

Ovarian cycle

Done by: Abdelhadi Okasha

- **Ovarian Cycle Overview**

→ The ovarian cycle refers to **cyclical changes in the ovary** that occur **every 28 days** (lunar month) during the **fertile period** of a **non-pregnant female**.

- → It is divided into **three main phases**:

Preovulatory (Follicular) Phase

Ovulation

Postovulatory (Luteal) Phase

- **Hormonal Control**

The **hypothalamus** releases **GnRH (Gonadotropin-Releasing Hormone)**, which stimulates the **anterior pituitary** to secrete:

- **1. FSH (Follicle Stimulating Hormone)** – Active in the **first phase**: Stimulates **maturation** of the primary follicle into a **Graafian follicle**. Stimulates **follicular cells** to secrete **estrogens**.

- **2. LH (Luteinizing Hormone)** – Acts in the **second phase**: Induces **final maturation** of the Graafian follicle and **ovulation**. Converts the ruptured follicle into a **corpus luteum**. Stimulates the corpus luteum to secrete **progesterone**.

- **I. Preovulatory (Follicular) Phase – First half of the cycle**

FSH stimulates several **primordial follicles** to begin development. Only **one follicle matures fully**, secreting **estrogen**.

Estrogen:

Inhibits FSH to prevent further follicle development.

Stimulates LH secretion, causing **atretic degeneration** of remaining follicles.

Triggers the **proliferative phase** of the **uterine cycle**.

- **II. Ovulation**

LH plays a central role:

Activates **collagenase**, which digests the **collagen fibers** around the mature follicle.

Increases **prostaglandins**, causing **ovarian contraction**.

Result: **Rupture of the mature Graafian follicle**, releasing the **secondary oocyte** along with the **corona radiata** and **zona pellucida**.

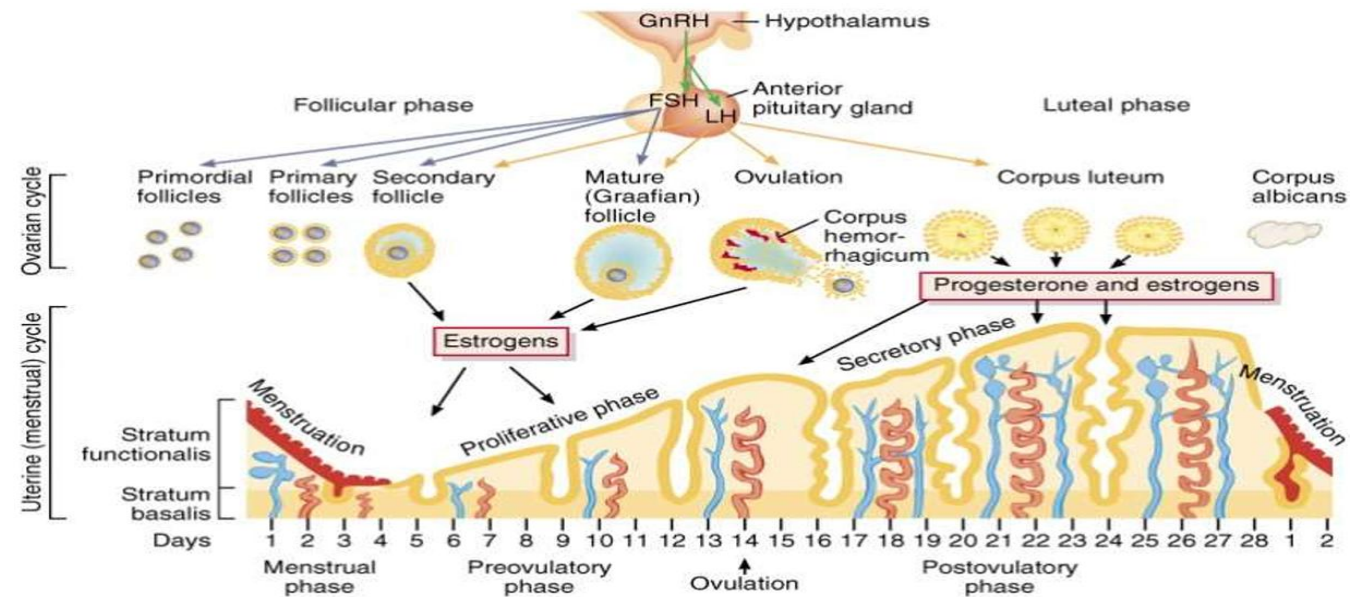
- **III. Postovulatory (Luteal) Phase**

After **ovulation**, **luteinizing hormone (LH)** causes the **membrana granulosa** and **theca interna** cells to transform into **luteal cells**, forming the **corpus luteum**.

- The **corpus luteum** secretes **progesterone**, which:

Triggers the **secretory phase** of the **uterine cycle**.

Inhibits LH secretion from the pituitary gland.



- **Fate of the Corpus Luteum**

A. If fertilization does not occur:

The corpus luteum **degenerates** approximately **9 days after ovulation**.

It becomes a **fibrous structure** called the **corpus albicans**.

Degeneration leads to a **drop in blood progesterone levels**

B. If fertilization occurs:

The corpus luteum becomes the **corpus luteum of pregnancy**.

It is maintained until the **4th month of pregnancy** by **human chorionic gonadotropin (hCG)** from the embryo.

Afterward, the **placenta** takes over and continues to secrete **progesterone** until **labor**.

Uterine cycle

Done by: Abdelhadi Okasha

- **Definition:** The uterine cycle consists of cyclical changes in the endometrium (mucous membrane of the uterus) that occur every 28 days during the fertile period of a non-pregnant female. It is regulated by the ovarian hormones and mirrors the ovarian cycle.

The cycle includes three phases:

Menstrual Phase
Proliferative Phase (Estrogenic or Postmenstrual)
Secretory Phase (Premenstrual or Progestational)

- **Uterine Wall Structure**

The uterine wall has three layers:

Perimetrium – outermost serous (peritoneal) layer.

Myometrium – middle muscular layer of smooth muscle.

Endometrium – inner mucosal layer; undergoes cyclic changes.

- **Endometrial layer during secretory phase**

Stratum functionalis:

- Supplied by long spiral arteries, which are dilated by progesterone.

- Sheds during menstruation.

Stratum basalis:

- Supplied by short straight arteries.

- Does not shed; forms the regenerative layer responsible for repair of glands and arteries post-menstruation.

- **I. Menstrual Phase (Day 1–5)**

- Corresponds to the early follicular phase of the ovarian cycle.

- Cause: Sharp decrease in progesterone (and estrogen) at the end of the previous cycle → constriction of spiral arteries → ischemia and shedding of the functional layer.

- The degenerating tissue, mucus, and unclotted blood (due to proteolytic enzymes) are expelled.

- The basal layer remains intact, and the endometrium becomes thin.

- **II. Proliferative Phase (Day 6–15) (Estrogenic or Postmenstrual Phase)**

- Corresponds to the late follicular phase of the ovarian cycle.

- Regulated by estrogen from the developing follicle.

- Endometrium thickens, blood supply increases, and mucous glands enlarge.

- Regeneration of endometrial glands and spiral arteries occurs from the basal layer.

- **III. Secretory Phase (Day 16–28) (Premenstrual or Progestational Phase)**

Corresponds to the luteal phase of the ovarian cycle.

Controlled mainly by progesterone (from the corpus luteum) and to a lesser extent by estrogen.

Endometrium:

- Greatly increases in thickness

- Arteries become spiral

- Glands become long, coiled, and filled with secretion

- Prepares the uterus to receive and nourish a blastocyst if fertilization occurs.

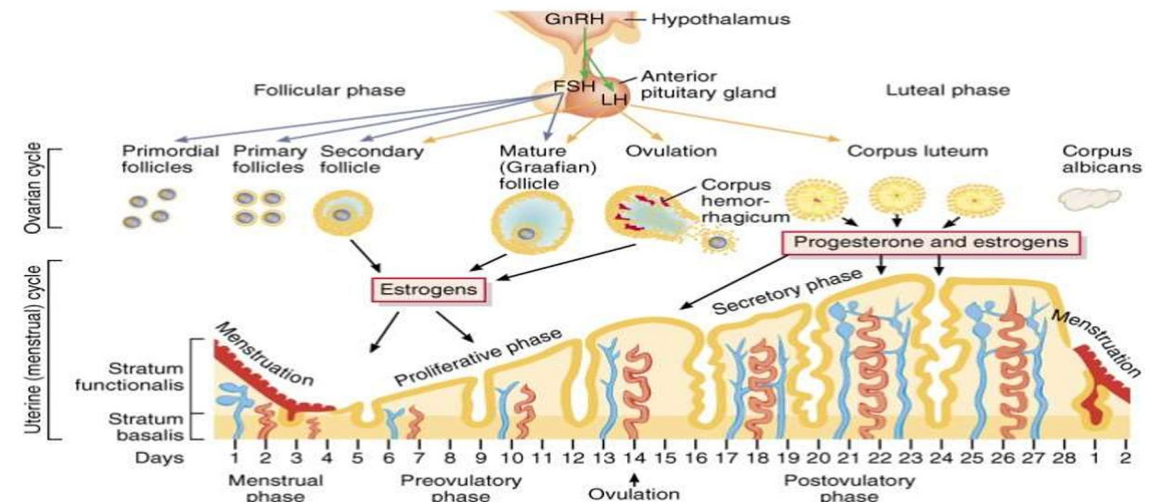
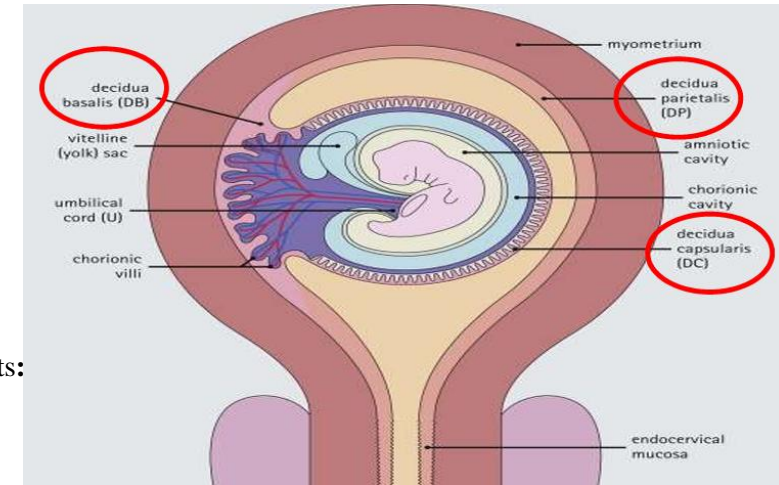
- **Decidua of Pregnancy:** the transformed endometrium in pregnancy and has three parts:

- 1) Decidua basalis – between fetus and myometrium; maternal part of the placenta.
- 2) Decidua capsularis – surrounds the fetus.
- 3) Decidua parietalis : lines remainder of uterine cavity.

- **If fertilization does not occur:**

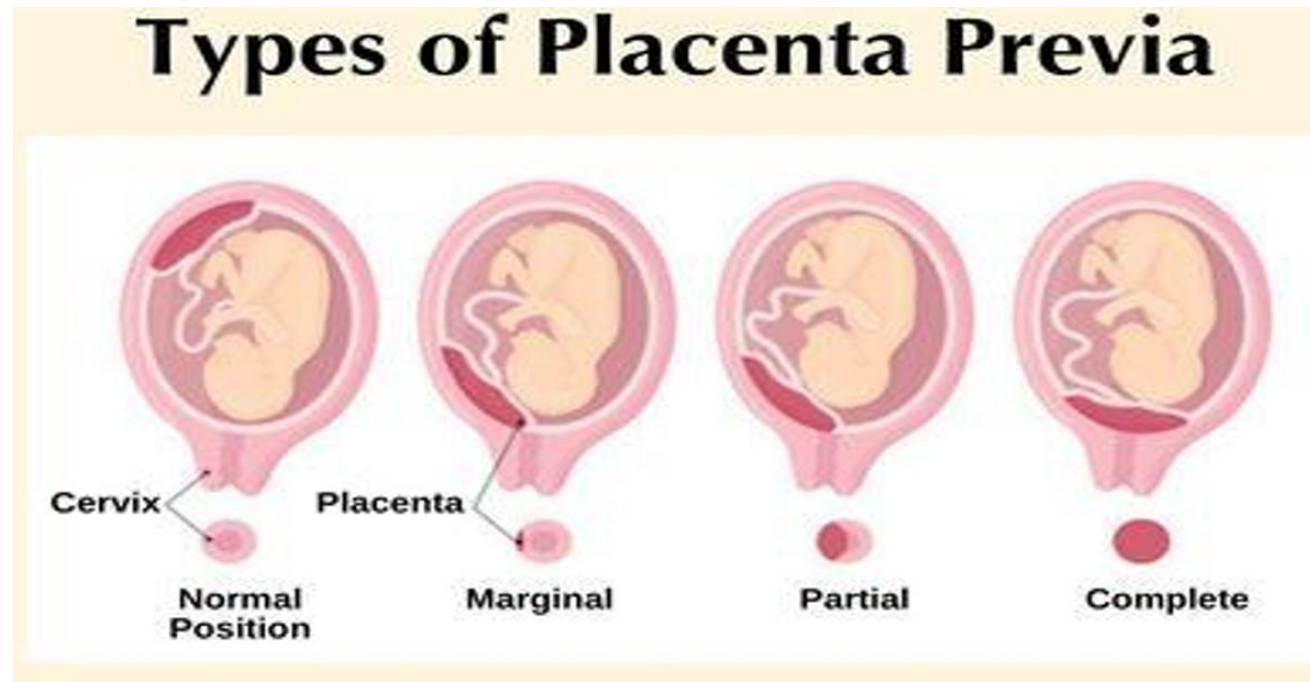
Corpus luteum degenerates → progesterone drops + Spiral arteries constrict, causing ischemia and shedding of the functional layer → menstruation begins

- **If fertilization occurs:** Corpus luteum becomes corpus luteum of pregnancy, continues to secrete progesterone. +Endometrium transforms into decidua to receive the blastocyst, which reaches the uterus 6 days after fertilization.



Cleavage + Implantation

Done by: Abdelhadi Okasha



- **Cleavage** refers to the series of **mitotic divisions of the zygote**, leading to the formation of the **morula** and eventually the **blastocyst**.

- **A. Formation of the Morula**

Cleavage occurs in the **uterine tube**, with the zygote dividing inside the **zona pellucida** into progressively smaller cells called **blastomeres**.

Development stages:

2-cell → 4-cell → 8-cell → 16-cell (morula)

The **morula** is a **solid ball of 16 blastomeres**, still enclosed by the **zona pellucida**. It reaches the **uterine cavity** on the **4th day** after fertilization.

- **B. Formation of the Blastocyst**

On **day 5**, the **zona pellucida** begins to degenerate.

Uterine fluid enters through the degenerated zona, creating **fluid-filled spaces** between central blastomeres.

These spaces **fuse to form a single cavity** called the **blastocoel**.

The **morula** transforms into a **blastocyst**, now made up of **50–60 blastomeres**.

The **blastocyst** comes into contact with the **uterine endometrium** by **day 5–6** post-fertilization.

- **Blastocyst Features**

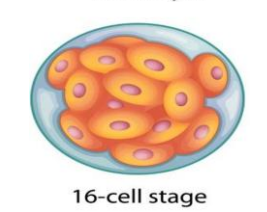
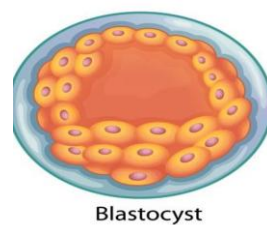
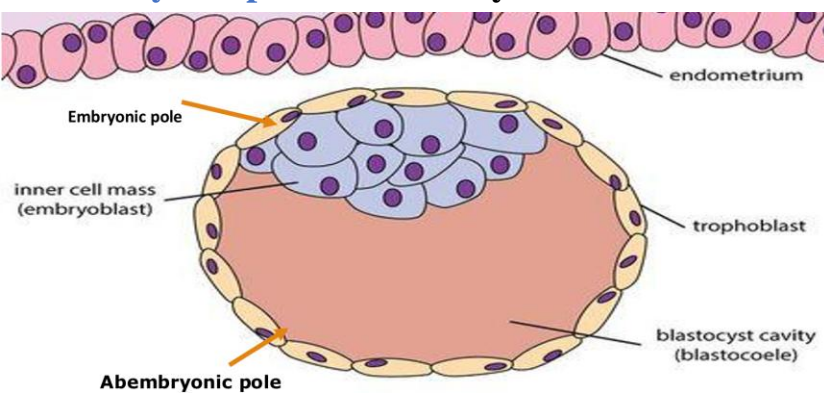
- 1. Two Cell Populations (separated by the blastocoel):**

Trophoblast (outer cell layer): Will form the **fetal membranes**.

Embryoblast (inner cell mass): Will form the **embryo**.

- 2. Two Poles: Embryonic pole:** Located **adjacent to the uterine endometrium**. +

Abembryonic pole: Faces **away from the endometrium**.



Implantation is the process by which the **blastocyst** penetrates the superficial layer of the **endometrium**.

Timing: Begins on **day 6 or 7** after fertilization & **Completed by day 11 or 12**.

Site: **Upper part of the posterior wall** of the **uterine body** is the most common and ideal implantation site.

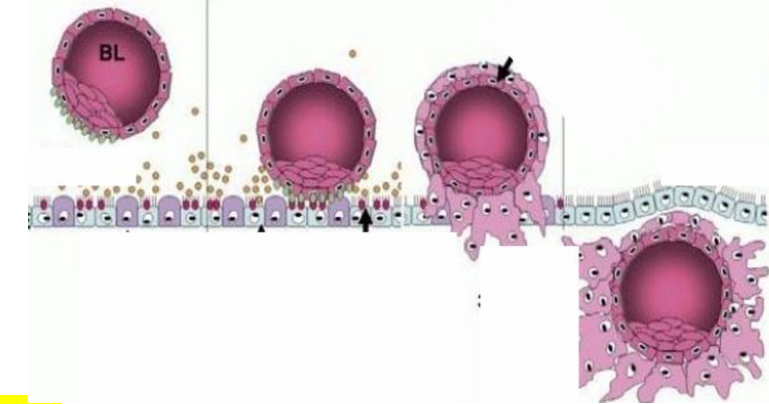
Mechanism of Implantation

1) The **embryonic pole** of the blastocyst makes contact with the **endometrial surface**.

2) **Trophoblast** cells at the embryonic pole secrete **enzymes** that **erode the endometrial mucosa**, creating a **defect**.

3) The blastocyst **enters the endometrium** through this defect.

4) Once embedded: The defect is initially **sealed by a blood clot** & Later, **surface epithelium proliferates** to fully cover the site.



- **Abnormal Sites of Implantation**

- A. Outside the Uterus (Ectopic Pregnancy)**

- **Tubal Pregnancy** (most common): In the **uterine tube**, often **ruptures within 1–2 months**, causing **internal hemorrhage**.

- **Ovarian Pregnancy**: Implantation occurs in the **ovary**.

- **Abdominal Pregnancy**: Implantation in the **abdominal cavity**, often near the **peritoneum** or **omentum**.

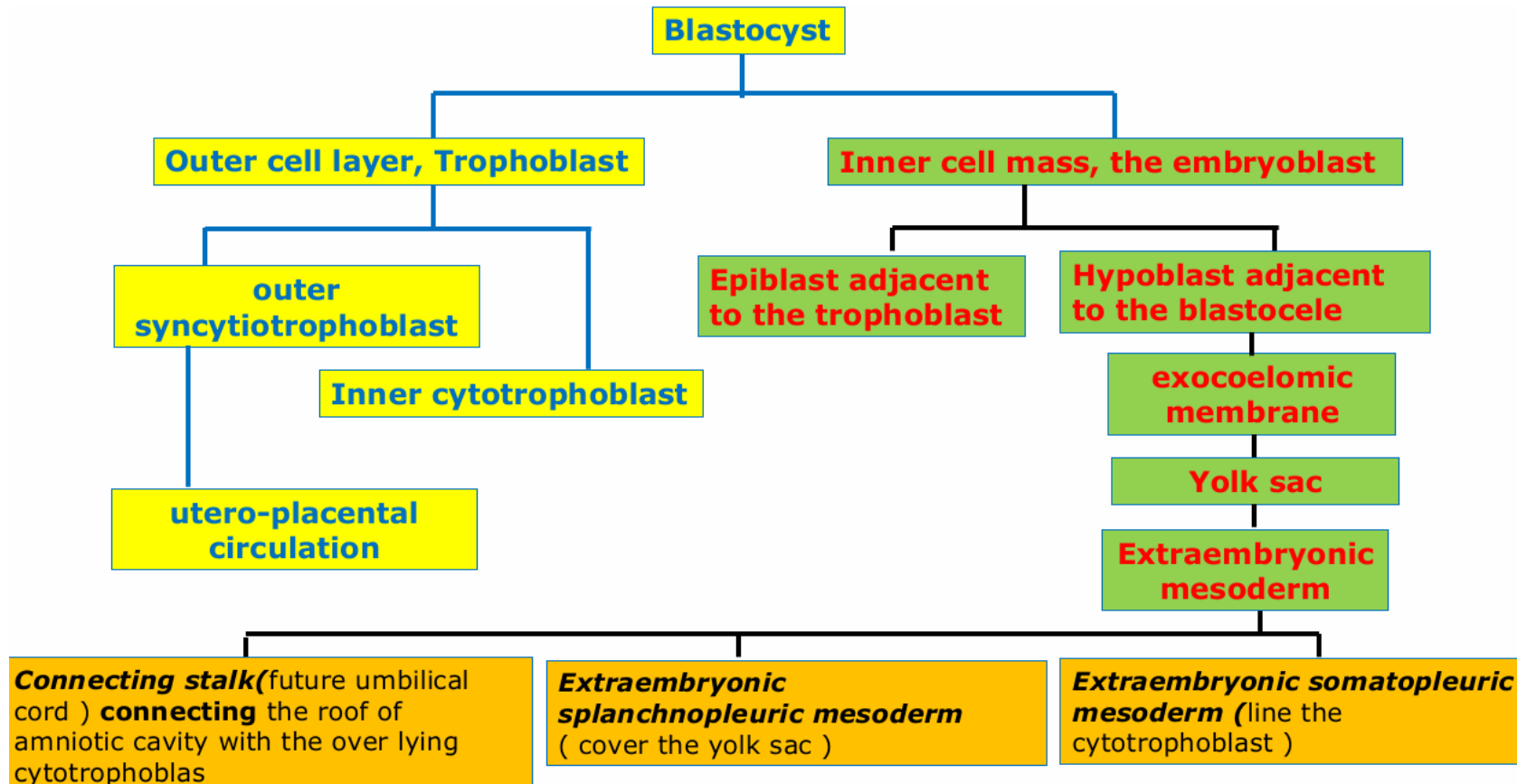
- B. Inside the Uterus – Placenta Previa** (Implantation in the lower uterine segment, leading to **placenta previa**)

- Three types: (Picture in previous slide)

Complications: Risk of **maternal hemorrhage** before delivery (**antepartum hemorrhage**).+ Potential **fetal death** + **Cesarean section** is recommended for safe delivery.

Second Week of Development

Done by: Abdelhadi Okasha



- During the second week of pregnancy, implantation is completed by the 11th or 12th day after fertilization. The embryoblast undergoes changes, forming the bilaminar germ disc. The epiblast lies adjacent to the trophoblast and forms the floor of the developing amniotic cavity, while the hypoblast lies next to the blastocoel. The bilaminar disc has a rounded or oval shape.
- The trophoblast develops more rapidly than the germ disc and differentiates into two layers: an inner cytotrophoblast composed of cells that retain their boundaries, and an outer syncytiotrophoblast which is a multinucleated layer lacking distinct cell borders. By the 9th day, small spaces form within the syncytiotrophoblast at the embryonic pole, then spread throughout to form trophoblastic lacunae, marking the lacunar stage. By the 11th and 12th days, the syncytiotrophoblast erodes maternal sinusoids, allowing maternal blood and uterine secretions to enter the lacunae and initiate the utero-placental circulation. This provides nourishment and allows gas and metabolite exchange for the developing germ disc. By the end of the second week, primary chorionic villi begin to appear at the embryonic pole.
- Two cavities form during this week. The amniotic cavity appears by the 8th day between the epiblast and the cytotrophoblast. Epiblast cells flatten to form amnioblasts, which constitute the roof of the amniotic cavity, while the floor is made by the epiblast itself. The primary yolk sac forms around the 9th day when hypoblast cells produce a layer of flat cells called the exocoelomic (Heuser's) membrane, which lines the blastocoel. This cavity, enclosed by the hypoblast and Heuser's membrane, becomes the primary yolk sac, replacing the original blastocoel. By day 13, the hypoblast produces additional cells that migrate into Heuser's membrane, proliferate, and form a new cavity called the secondary yolk sac.
- Extraembryonic mesoderm appears as loose tissue between the cytotrophoblast and the yolk sac, originating from yolk sac cells. Cavities develop within it and fuse to form a large C-shaped space called the extraembryonic coelom or chorionic cavity. A structure called the connecting stalk, the future umbilical cord, is formed from extraembryonic mesoderm and connects the amniotic cavity with the overlying cytotrophoblast.
- The extraembryonic mesoderm is divided by the chorionic cavity into extraembryonic somatopleuric mesoderm, which lines the cytotrophoblast, and extraembryonic splanchnopleuric mesoderm, which covers the yolk sac. The connecting stalk is located dorsally and links the roof of the amniotic cavity to the cytotrophoblast. The combination of the cytotrophoblast, syncytiotrophoblast, and extraembryonic somatopleuric mesoderm is collectively called the chorion. By the 12th day, the blastocyst is referred to as the chorionic vesicle.

